

Efficacy of Carnoy's solution as an adjunct to conventional treatment modalities in aggressive Bony Tumors.

Parul Tandon*, Harish Saluja**, Seemit Shah***, Anuj Dadhich**, Shivani Sachdeva**

Abstract-

Odontogenic tumors sometimes have aggressive behavioral pattern which leads to recurrence after conventional surgical approaches. Odontogenic keratocystic tumor (KCOT) is one of the most aggressive odontogenic cysts with a high recurrence rate, this was explained histopathologically as it typically shows a thin, friable wall, which is often difficult to enucleate from the bone in one piece. Various treatment modalities were introduced including decompression, marsupialization, enucleation with or without Carnoy's solution and resection. Conservative treatment with enucleation and application of Carnoy's solution can be used specially in the large lesions that when treated with resection, the continuity of the jaw will be interrupted. This technique shows comparable results to other more aggressive techniques.

Keywords- Keratocystic odontogenic tumor, Carnoy's solution, Surgical treatment, Recurrence

Introduction-

Bony lesion with aggressive behavior, regardless its "benign" nature, necessitates a more radical surgical approach. Odontogenic tumors like ameloblastoma and keratocystic tumor (KCOT) are the most aggressive odontogenic tumors with a high recurrence rate as there is presence of satellite cysts within their fibrous walls. Moreover KCOT typically shows a thin, friable wall, which often tears while enucleation.[1] Therefore, treatment should aim to eliminate the possible vital cells left behind in the defect. For this reason a mild, not deeply penetrating, cauterizing agent is used such as Carnoy's solution {consists 3 ml of chloroform, 6 ml of absolute ethanol, 1 ml of glacial acetic acid and 1 g of ferric chloride}.[2] A significant decreased recurrence rate is reported in literature in cases where complimentary Carnoy's Solution is used. The aim of this paper is to report a case of mandibular KCOT and was treated with

conventional method of enucleation along with Carnoy's solution over the inferior alveolar plexus without any definitive damage to lip sensitivity.

Case report-

A 36-year-old man reported to the department of oral and maxillofacial surgery with a dull pain in right lower back region of jaw since 6 months. On clinical examination no obvious extraoral swelling was appreciated while intraoral palpation showed buccal cortical expansion over right mandibular premolar-molar region. A panoramic radiographic image showed a radiolucent, multilocular well-defined lesion extending from the right ramus-angle region to canine region (Fig 1).

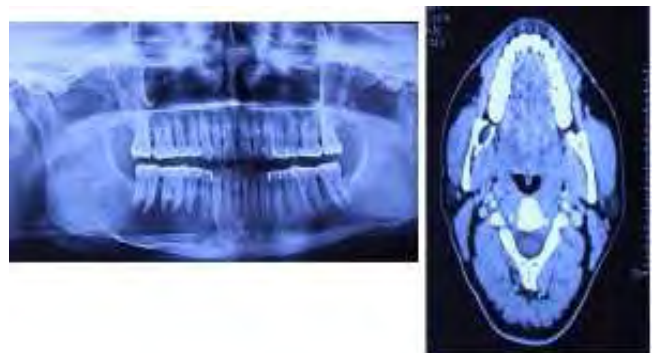


Fig 1: Preoperative Radiograph showing multilocular radiolucency

*Senior lecturer, **Reader, ***Professor & HOD, **Reader

Department of oral & maxillofacial surgery

**Reader, Department of Periodontics

Corresponding author-

Rural Dental College,
PIMS, Loni, Maharashtra (413736).

KCOT was histologically confirmed after incisional biopsy. Informed written consent was taken from the patient and ethical committee approval was taken from Institutional ethical committee board. Mucoperiosteal flap was raised and buccal cortical osteotomy was performed to reach the bed of lesion. Enucleation of the lesion by intra approach was accomplished under general anesthesia (Fig 2).

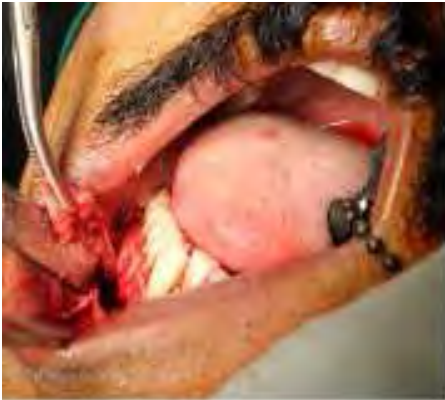

Fig 2: Intraoperative-Enucleation of pathological lining following peripheral osteotomy

Soft tissues adhering to the capsule of the lesion in the lingual fenestration were also removed. In the proximity of the mandibular canal, the capsule of the lesion was dissected from the inferior alveolar plexus. This was followed by single application of Carnoys solution imbibed gauze pellets for 5 min. Before the application of Carnoys solution care was taken to isolate the surrounding soft tissues and liquid paraffin soaked gauze was placed over the inferior alveolar nerve to prevent its damage. It is important to count the gauze pellets while placing and removing from the cavity to prevent and left overs inside the defect. Then, the lumen of the defect was re-rinsed with copious saline to flush off the solution from the bony cavity which sighted dark brown colored and fixated (Fig 3). Closure of flap was done by horizontal

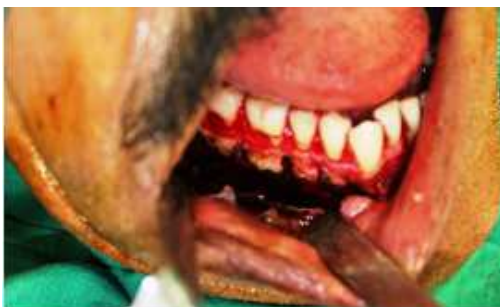

Fig 3: Application of Carnoys solution

mattress sutures using 3-0 vicryl (Fig 4). In the immediate postoperative period, the patient presented with paresis of the lower lip, which had a total regression after 7 months. After a period of 1 year, no sign of recurrence was observed.

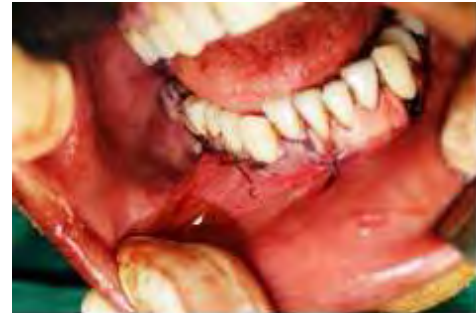

Fig 4: Postoperative: Closure done

Discussion-

Carnoys's solution was first used as a medicament in surgery by Cutler and Zollinger in 1933.[3] composed of ferric chloride 1 gram, chloroform 3ml, glacial acetic acid 1ml and absolute alcohol 6ml. It is used as a fixative agent where absolute alcohol hardens the tissue by shrinking it, glacial acetic acid swells tissue and prevents overhardening, chloroform increases the speed of fixation and ferric chloride acts as a dehydrating agent.[4]

Success of the application of this medicament after enucleation of aggressive lesions is thought to be due to both penetration and fixation action. Its average depth of penetration is 1.54mm after 5 mins of application.[5] Alteration in the neural conductivity after direct application of carnoys solution over 2 minutes has been reported in literature.[6] However The neuronal damage can be prevented by coating the nerve using separating media like vaseline or liquid paraffin as was done in our case. Our patient developed paresthesia over right half of lower lip however that was transient and gradually disappeared completely after 7 months.

Among all the ingredients of carnoys solution, chloroform is considered to be very hazardous and should be used in a ventilated hood by wearing masks. Exposure to chloroform has been associated with cancer and reproductive toxicity.[7] Thus FDA in 2013 ban the use of chloroform and adopted a modified Carnoy's solution (designated "Carnoys MC" containing Ferric chloride 1gram, Glacial acetic acid 1ml and Absolute alcohol 6ml to distinguish it from the original solution containing

chloroform, "Carnoy's CS") in the treatment of KCOT and ameloblastomas.[8] This has led to widespread confusion among surgeon and pharmacists all over the world. In an attempt to clarify the dilemma that surrounds this topic of discussion, a short questionnaire was drafted and distributed to members of the American Association of Oral and Maxillofacial Surgeons (AAOMS) listed. The web-based survey showed that of 6,880 members listed in the 2013 in American Association of Oral and Maxillofacial Surgeons directory, 56% of whom were using the solution with chloroform and 42% were using it without chloroform 42% with no complications specifically pertaining to its use. Since then, no restriction on the use of chloroform has been advocated.[9]

It is a powerful fixative, haemostatic and cauterizing agent which penetrates cancellous spaces in the bone and devitalizes and fixes the left out tumour cells. It promotes chemical necrosis of up to 1.5 mm and elimination of epithelial remnants and possible microcysts.[10] In a systematic review done by Blanas et al. (2000)[11], the authors reported that resection was found to have the lowest recurrence rate (0%) but the highest morbidity rate, while enucleation with application of Carnoy's solution can result in a recurrence rate comparable to that of resection without unnecessarily aggressive surgery. We prefer keeping in hold the most radical and aggressive therapeutic option like resection of jaw should only in cases of KCOT with frequent recurrences as resection of the jaw causes significant functional and aesthetic problems to the patient and encourage the application of Carnoy's solution after a slight peripheral ostectomy over the remaining bony surgical bed. This promotes mechanical regularization of the bone cavity as well as the mechanical removal of any soft tissue left behind, decreasing the likelihood of a recurrence.

Conclusion-

Enucleation of the lesion along with and the use of Carnoy's solution showed uneventful healing in a 1 year postoperative period. Therefore, we believe that the choice of this surgical method in treating aggressive intraosseous lesions is a rational approach to reduce recurrence. However, due to the possibility of late recurrence, a long-term postoperative follow-up is needed

References-

1. Morgan, T.A., Burton, C.C., Qian, F.A retrospective review of treatment of the odontogenic keratocyst. J. Oral Maxillofac. Surg 2005;63:635–639.
2. Chirapathomsakul, D., Sastravaha, P.A review of odontogenic keratocysts and the behavior of recurrences. Oral Surg. Oral Med. Oral Pathol.OralRadiol.Endod 2006;101: 5–9.
3. Cutler EC, Zollinger R. Sclerosing solution in the treatment of cysts and fistulae. Am JSurg 1933;19:411.
4. Stevo Matijević, Zoran Damjanović, Zoran Lazić, Milka Gardašević, Dobrila Radenović-Djurić. Peripheral ostectomy with the use of Carnoy's solution as a rational surgical approach to odontogenic keratocyst: A case report with a 5-year follow-up Vojnosanit Pregl 2012; 69(12): 1101–1105.
5. Lau SL, Samman N. Recurrence related to treatment modalities of unicystic ameloblastoma: a systematic review. Int J Oral Maxillofac Surg 2006;35:681–90.
6. Sivaram Sivanmalai, Kohila Kandhasamy, Chandrakala Shekarappa Annapurna Pannaikadu Somasundaram Prabu Carnoy's solution in the management of odontogenic keratocyst Journal of Pharmacy & Bioallied Sciences J Pharm Bioallied Sci. 2012; 4: S183–S185.
7. Fabrizi L, Taylor GW, Can˜as B, Boobis AR, Edwards RJ. Adduction of the chloroform metabolite phosgene to lysine residues of human histone H2B. Chem Res Toxicol 2003;16:266–75.
8. American association of oral and maxillofacial surgeons J Oral Maxillofac Surg 2015; 73:2132—2135.
9. Ecker J, Horst RT, Koslovsky D Current Role of Carnoy's Solution in Treating Keratocystic Odontogenic Tumors Journal of oral maxfac surg 2016; 74(2): 278–282
10. Stoelinga JWP. Long-term follow-up on keratocysts treated according to a defined protocol. In J Oral Maxillofac Surg 2001; 30(1): 14–25.
11. Blanas, N., Freund, B., Schwartz, M., Furst, I.M., 2000. Systematic review of the treatment and prognosis of the odontogenic keratocyst. Oral Surg. Oral Med. Oral Pathol.OralRadiol.Endod 2000; 90:553.